Archives of
Medical and Clinical Case Studies
Volume 3, Issue 1

Case Report

De Novo Autoimmune Hepatitis Masquerading as Drug Induced Liver Injury: Case Report and Literature Review

Kanuri SH[1], Fish M.H[2] and Cameron B[3]

[1] Sri Harsha Kanuri, The Cameron Clinic, Longview, TX, USA
[2] Melton Fish, Department of Pathology, Christus Health Good Shepherd Medical Center, Longview, TX, USA
[3] Benjamin Cameron, The Cameron Clinic, Longview, TX, USA

***Corresponding author:** Sri Harsha Kanuri, The Cameron Clinic, Longview, TX, USA

Received Date: December 31, 2024; **Accepted date:** January 07, 2025; **Published Date:** January 11, 2025

Citation: Sri Harsha Kanuri, Arch Med Clin Case Stud, "De Novo Autoimmune Hepatitis Masquerading as Drug Induced Liver Injury: Case Report and Literature Review". 2025; 3(1): 120

Copyright: © 2025 Sri Harsha Kanuri. This is an open-access article distributed under the terms of theCreative Commons Attribution License.

Abstract

Introduction: Autoimmune hepatitis (AIH) is an immune mediated destruction of hepatocytes, where immune system is hyper activated and revamped to attack the self-antigens unmasked in the liver. It usually occurs when pertinent environmental factors interact in genetically susceptible individuals. Most commonly, it is seen in females with autoimmune diseases. It is mainly classified into AIH-I and AIH-II. It can present itself as acute or chronic liver failure. Clinically, it can feign as viral hepatitis, drug-induced hepatitis, non-alcoholic steatohepatitis (NASH), thence should be carefully discerned based on the clinical profile and pertinent autoimmune workup. Prompt diagnosis is necessary so that immunosuppression with steroids is recommended to prevent immune mediated destruction and progression to cirrhosis

Case presentation: A 72-year old female patient presented with mildly elevated liver enzymes and liver biopsy uncovered drug-induced liver injury (DILI). She was treated with prednisone and her current medications were stopped. After her steroids were discontinued, she developed a relapse with a substantial flare-up of LFTs with histopathology unveiling AIH, and prednisolone was restarted. She also developed co-existent IVC thrombosis and thrombocytopenia.

Results: Biopsy showed portal hepatitis, interface hepatitis, bridging necrosis, epithelioid granuloma and giant cell transformation of hepatocytes. Portal tracts expanded by necro-
inflammatory infiltrate LFTs; AST: 218, ALT 255, bilirubin: 2.2, ALP: 202, ANA: positive (1:640), AMA & ASMA: negative. The differential diagnosis is more consistent with autoimmune like drug-induced hepatic injury vs de-novo autoimmune hepatitis.

Conclusions: This is a classic case of autoimmune hepatitis. Even though her hepatitis is precipitated by drugs (Statins), there might just serve as intercessors for unmasking the self-antigens and triggering autoimmune mediated onslaught on hepatocytes for inception of hepatitis. Moreover, cessation of steroid therapy does not a cause relapse of DILI whereas resurgence of AIH is a habitual phenomenon that materializes within few months of immunosuppression suspension.

Keywords: Autoimmune hepatitis, drug induced hepatitis, autoimmunity, self-antigens, autoantibodies, molecular mimicry, steroids, hypercoagulability, deep vein thrombosis.

Introduction:

Autoimmune hepatitis (AIH) is caused by immune-mediated destruction of hepatocytes due to hyperactivation of the immune system in genetically predisposed individuals [1]. Histologically, it characterized by the presence of bridging necrosis, interface hepatitis and lobular inflammation[2]. AIH is hypothesized to result from exposure to provoking environmental factors in individuals who are intrinsically predisposed. Some of the environmental factors proposed to provoke autoimmunity in AIH include infections, alcohol use, vitamin D deficiency, disruption of the intestinal microbiome, female hormones, exposure to drugs and herbal agents [3]. These factors then trigger the onset of AIH in genetically susceptible individuals through pathological aberrations marked by impairment of immune system regulation, hyperactivation of the cellular components of immune system, overproduction of autoantibodies, and molecular mimicry of hepatocyte antigens [3]. The annual incidence and prevalence of AIH are roughly 0.67-2 and 4-24.5 per 100,000 population, respectively [4, 5]. It tends to be more common in females than males (4:1) who have more proclivity to develop autoimmune related disease pathologies due to their hormonal profile and genetic traits [1]. AIH can be asymptomatic or present itself with acute onset of nausea, malaise, fever, arthralgia, jaundice, dark urine and weakness. It may also progress to chronic liver failure with anasarca, ascites, hepatomegaly, splenomegaly and encephalopathy [6]. AIH is classified into Type I and II. Type I AIH is the most common and occurs in both children and adults. Type II is less common, accounting for 5-10% of AIH cases, and predominantly affects children [1]. Because the clinical presentation is non-specific, AIH must be corroborated by elevation of LFTs, presence of specific autoimmune antibodies, increased IgG levels, and finally through telltale histopathologic changes identified by liver biopsy[7]. Upon diagnosis of AIH, treatment is aimed at suppressing the immune-mediated inflammatory attack directed against hepatocytes, with the goal of achieving and maintaining biochemical and histological remission[8], ultimately preventing chronic liver failure, cirrhosis, and hepatocellular carcinoma [1, 7]. Most commonly, corticosteroids and azathioprine are used to induce and maintain disease remission [1, 7]. In the event of a sub-therapeutic response to these first-line agents, patients should be referred to a center specializing in hepatology in order to confirm the diagnosis and consider alternative immunosuppressive therapies[8]. Studies have shown that the typical duration of treatment needed to induce remission is approximately 2 years[9]. Unfortunately, other clinical studies have found remission rates of only 40% patients even after 3-5 years of immunosuppressive therapy [1]. Nevertheless, the success of immunosuppressive therapy should be frequently monitored with liver enzymes, bilirubin and immunoglobulins. In most instances, the decision to administer long term immunosuppressive therapies should be carefully weighed and considered depending upon on factors such as patient's response, disease-free interval, age of patient, side effects, progression of disease pathology on histology and life expectancy of the patient. It is estimated that the 1, 3, 5, & 10 mortality of patients with diagnosis of AIH is roughly 85.4%, 65.4%, 56.4% & 39.4%[7]. As AIH progresses to chronic hepatitis and cirrhosis without treatment, the subsequent risk of developing a hepatocellular carcinoma is around 3.3%-5.1%[7].

Here, we present the case of a 72-year old female with a longstanding history of well-controlled hypertension and hyperlipidemia, who presented with new elevations in hepatic aminotransferases on a routine office visit. Despite discontinuation of pravastatin, which she had been treated with for years, AST and ALT continued to increase. A liver biopsy was obtained and felt to be most consistent with "Autoimmune-Hepatitis-Like" Drug Induced Liver Injury (DILI), presumably due to her prior treatment with pravastatin. Prednisone was initiated, serial LFTs normalized, and prednisone was tapered over the course of several months. Her LFTs remained within the normal range for several months after discontinuation. After approximately 8 months, ezetimibe was started for treatment of hypercholesterolemia and a month later, liver transaminases again began trending up. The patient was again treated with prednisone and a second liver biopsy was obtained, suggesting Autoimmune

Hepatitis versus DILI. After a 10-month course of corticosteroids, AST and ALT returned to normal range, and the patient was ultimately started on azathioprine. This clinical scenario represents a classic case of AIH, and also illustrates the similar histopathological findings in both AIH and DILI. A key difference between these two diagnoses is important to consider: discontinuation of steroid therapy does not a cause a relapse of DILI, whereas recurrence of AIH is commonly seen after discontinuation of corticosteroids

Case report:

A 72-year old women with a past medical history of well-controlled hypertension and hyperlipidemia presented for a routine office visit in late 2022 and was noted to have elevation of liver aminotransferases. Repeat testing showed worsening elevations, and subsequent viral hepatitis evaluation was negative. The patient denied significant alcohol use. Pravastatin was discontinued without effect. She subsequently underwent a liver biopsy, with pathological diagnosis of "Autoimmune-Hepatitis Like" Drug-Induced Liver Injury (DILI). Her ANA was positive, but her ASMA was negative. She was treated with prednisone, initially 40 mg daily and subsequently tapered, from October 2022 to January 2023, with complete resolution. At this point, pravastatin was felt to be the culprit. In December 2023, the patient was started on ezetimibe for atherosclerotic cardiovascular risk reduction. A month later, labs indicated recurrence of transaminitis. Despite rapid initiation of a second course of prednisone and discontinuation of ezetimibe, serial testing showed a 10-fold increase of liver enzymes (AST, ALT & alkaline phosphatase). She underwent a second liver biopsy, and histopathological examination at this time again revealed AIH-Like DILI versus Autoimmune Hepatitis. The clinical background, however, was misreported to the pathologist, who was under the impression that the initial episode of hepatitis in 2022 occurred after starting ezetimibe, and the second episode occurred after rechallenging the patient with ezetimibe. Subsequently, the pathology was reviewed by a transplant hepatologist at a tertiary referral center, who concluded the diagnosis to be Autoimmune Hepatitis **(Fig 1-5)**. After several months on prednisone 40 mg daily, LFTs began to trend down, ultimately normalizing in November 2024. During this second course of corticosteroid treatment, the patient did experience two adverse events associated with corticosteroids: Steroid-induced gastritis, which was successfully treated with proton pump inhibitors, and a provoked IVC thrombosis **(Fig 6-7)**, incidentally found on serial hepatic ultrasound/CT and treated with apixaban. Current outpatient medications include calcium carbonate, cholecalciferol, cyclosporine, olmesartan, pantoprazole, and azathioprine. BP: 153/85 mm hg, HR: 66/min, Temp 96.5 F (35.9C), Height 165.1 cm, Weight 179 lbs, SPO2: 96 and BM2: 29.9 kg/min.

Histopathology

Liver Biopsy (9/14/2022)
Gross: The specimen consisted of one tan-red, slightly fragmented cylindrical core of tissues consistent with liver measuring 2.8 cm in length x less than 0.1 cm in diameter.

Microscopic: Examination of liver core biopsies demonstrated a single core of liver parenchyma showing portal and peri-venular inflammation and focal necro-inflammatory bridging. No evidence of fibrosis was seen on trichrome stain. The portal tracts were expanded by inflammatory infiltrate composed of lymphocytes, occasional neutrophils, eosinophils, poorly formed collection of histiocytes, and a single epithelioid granuloma (FIG 1-4). Very scant plasma cells were seen, as demonstrated by CD138 immunostaining. Numerous histiocytes (PAS-D positive) were seen. Marked bile proliferation was noted, with a few bile ducts showing an infiltration of neutrophils (Acute cholangitis) (FIG 2-3). The majority of the portal tracts showed at least mild interface hepatitis, but not circumferential. Extensive peri-venular dropout was seen, with numerous inflammatory cells and PAS-D positive histiocytes, consistent with peri-venular necrosis. Focally, there was portal vein to central vein bridging inflammatory activity. Iron staining performed with appropriate controls demonstrated +2 activity. Numerous apoptotic hepatocytes were seen. The PAS and PAS-D stain did not indicate alpha-1 antitrypsin activity.

Final comment: Biopsy showed portal hepatitis, with peri-venular necrosis with occasional bridging necrosis. These findings are more consistent with autoimmune-like drug-induced liver injury. No

evidence of autoimmune hepatitis. Clinical correlation is recommended.

Liver Biopsy (6/20/2024):

Gross: The specimen consisted of two mottled pale tan to tan, cylindrical cores of tissue with focal pinpoint erythema measuring 0.7 and 2.2 cm in length and each having an average diameter of less than 0.1 cm. The end of the small core displayed a more white-tan discoloration.

Microscopic: The biopsy included two cores of liver parenchyma 2.8 cm in length with eleven portal tracts adequate for evaluation. The liver architecture was markedly disturbed due to bridging necrosis **(FIG 1&3)**. Necroinflammatory activity extended from the portal vein to the central vein **(FIG 1-4)**. Trichrome staining of liver tissue revealed minimal fibrosis **(FIG 5)**. All the portal tracts were markedly expanded by dense inflammatory infiltrate consisting of lymphocytes, plasma cells, eosinophils, and histiocytes, poorly formed collections of histiocytes as well as established epitheloid granulomas in the portal tracts **(FIG 1-4)**. The periphery of the portal tract showed abundant bile ductutar proliferation **(FIG 2-3)**. Diffuse interface hepatitis was seen, almost circumferentially, inlcuding a majority of the portal tracts **(FIG 1-4)**. Multinucleated gaint hepatocytes were seen at the periphery of one of the portal tracts. Venular hepatic dropout and necrosis was seen as well as inflammatory cells. Individual apoptotic hepatocytes were also seen. Quite numerous and scattered lobular inflammation was noted. Iron stain shows minimum deposition with Kpuffer cells. PAS with and without diastase stains were unremarkable. Reticulin and trichrome stains showed minimal portal fibrosis. AFB and GMS stains were negative.

Final comments: The biopsy showed similar histological findings with prior biopsy with the addition of epithelioid granuloma **(FIG 5)** and giant cell transformation of hepatocytes. The differential diagnosis is more consistent with autoimmune like drug-induced hepatic injury vs de-novo autoimmune hepatitis. Liver function tests at the time of biopsy includes AST: 218, ALT 255, bilirubin: 2.2, ALP: 202, ANA: positive (1:640), AMA & ASMA: negative. Clinical note stated that after the first biopsy, the patient stopped the medication [erroneously believe to be ezetimibe] and was put on prednisone, and her LFTs improved. Later, however she stopped the prednisone and restarted ezetimibe with recurrence of transaminitis. The timeline re-challenging with medication pinpoints towards drug induced autoimmune like phenomenon. Clinical correlation is recommended.

Imaging studies

<u>Abdominal Ultrasound 12/12/2024</u>

High resolution sonographic examination of the abdomen revealed

Liver: unremarkable. Normal size and echotexture. No mass identified.

Gall Bladder: Unremarkable. No stones, wall thickening or peri-cholecystic fluid is negative. Negative murphy sign.

Pancreas: Unremarkable. No masses or dilation

Bile ducts: Common bile duct is not dilated.

Spleen: Unremarkable. Normal size and echotexture.

Kidneys: unremarkable. No masses or hydronephrosis.

Aorta: Appearance of partial filling defect in the IVC.

Final impression: Partial filling defect in the IVC. Recommended for follow-up with contrast enhanced CT for further assessment.

<u>CT Abdomen/Pelvis with contrast 12/12/2024 **(Fig 6-7)**</u>

Bones: Multilevel degenerative changes in the spine. Anterior and posterior fusion hardware at L3-L4. No Acute bone abnormality is seen.

Abdomen:
Small amount of non-occlusive thrombus in the IVC is described.

Cirrhotic morphology in the liver is noted. No mass identified.

No additional acute intraabdominal or pelvic process is identified.

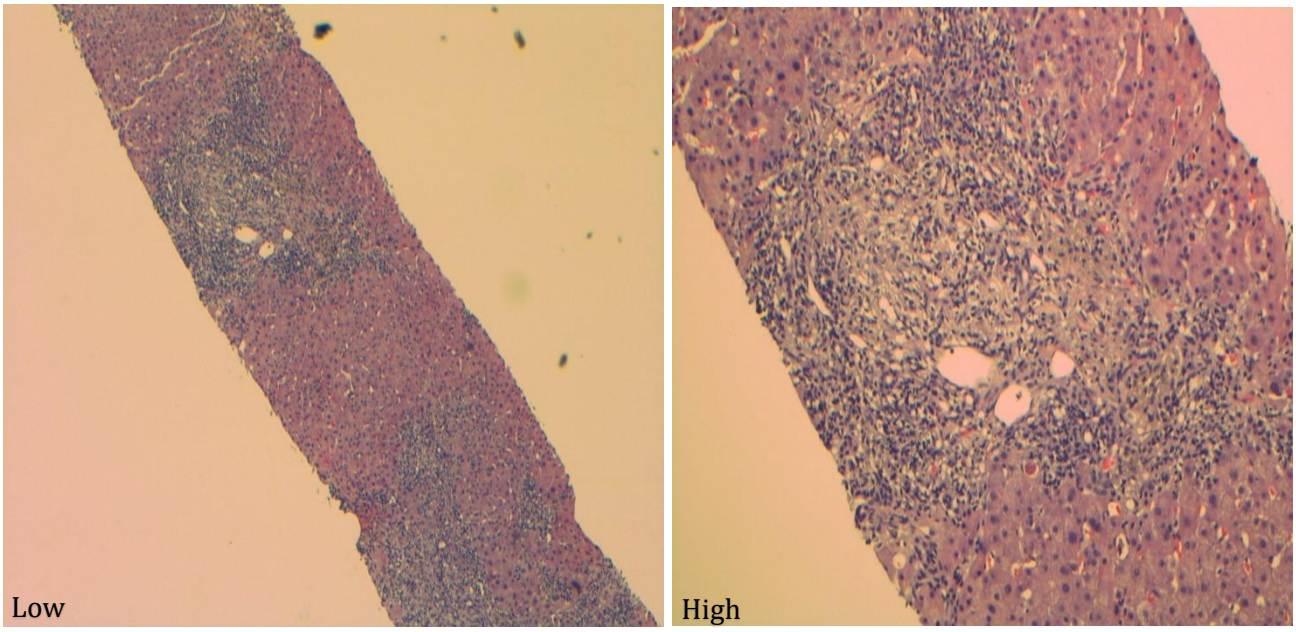

Figure 1: **Low and high magnification of liver tissue showing autoimmune hepatitis:** Microscopic examination revealed charateristic features of autoimmune hepatitis including bridging necrosis, diffuse interface hepatitis, portal vein necroinflammatory activity migrating towards the central vein, bile duct proliferation, epitheloid granulomas, venular hepatic dropout, apoptotic hepatocytes and scattered lobular inflammation.

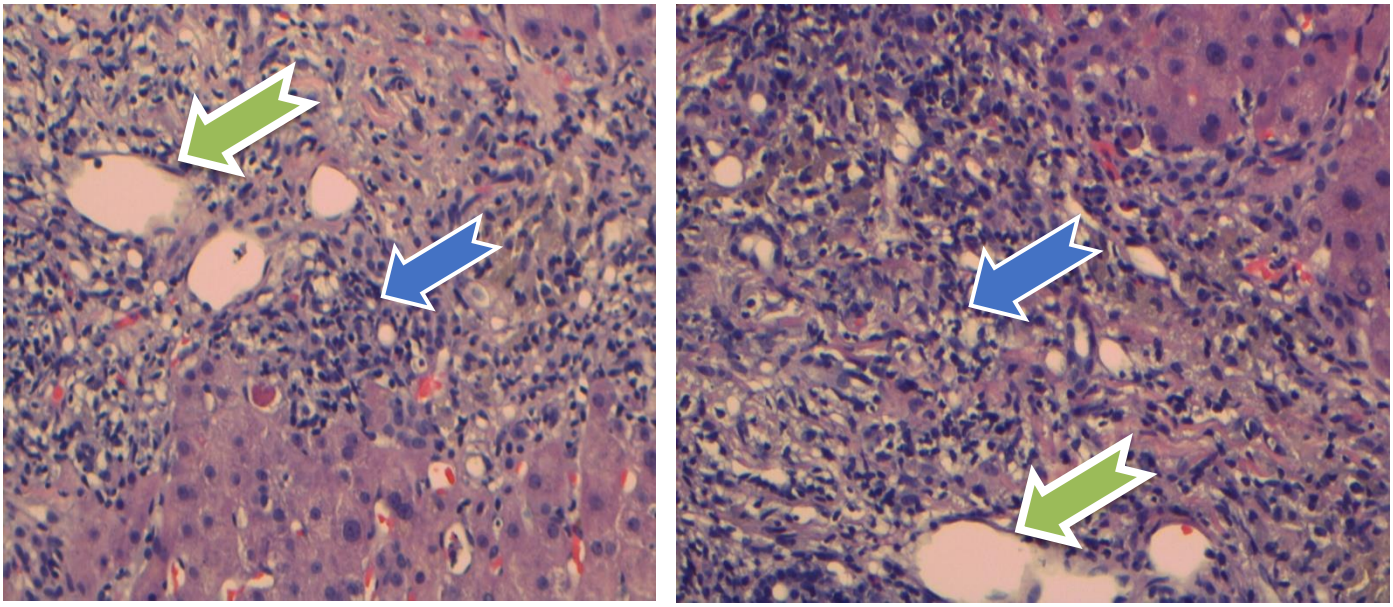

Figure 2: **High magnification of portal tract showing changes consistent with autoimmune hepatitis:** All the portal tracts are markedly expanded by dense population of mixed inflammatory infiltrate consisting of lymphocyes, plasma cells, eosinophils, histiocytes and poorly formed collection of histiocytes (Blue arrow). The periphety of the portal tract shows marked bile duct proliferation (Green arrow). Multinucleated gaint cells are noted at the periphery of the portal tract. In some areas, scattered epitheloid granulomas are also seen.

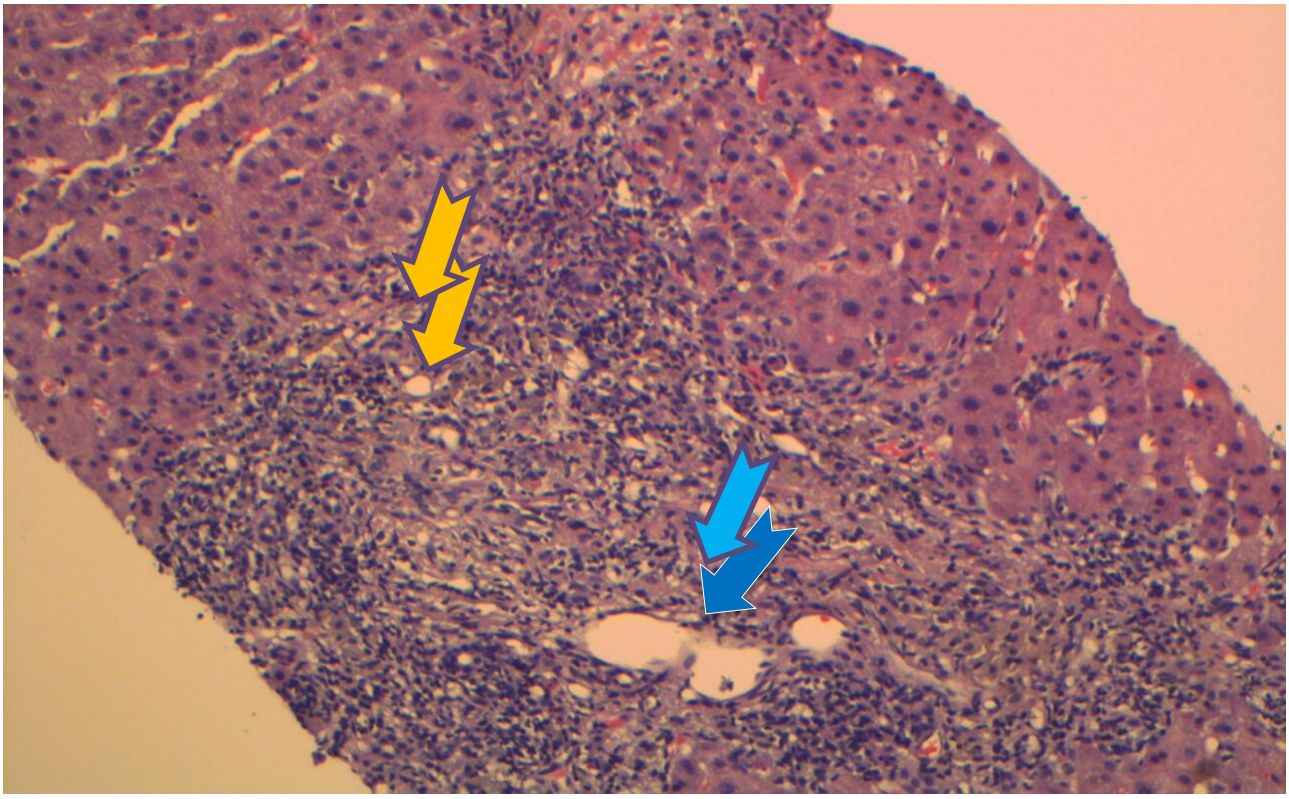

Figure 3: **High magnification of portal tract and liver lobule revealing changes of autoimmune hepatitis:** This section reveals a hepatic lobule with central vein (Green arrow) and portal vein (Blue arrow). Portal vein necroinflammatory infiltrate migrating towards the central vein is clearly seen. The liver architecture is markedly disturbed due to bridging necrosis, which is necrotic inflammation present in more than one area of liver lobule and extending to the adjacent lobule is seen. Periportal hepatitis, that is extension of inflammation from the portal area towards the periportal area and damage to the limiting plate is also seen. Also seen us the scatered lobular inflammation.

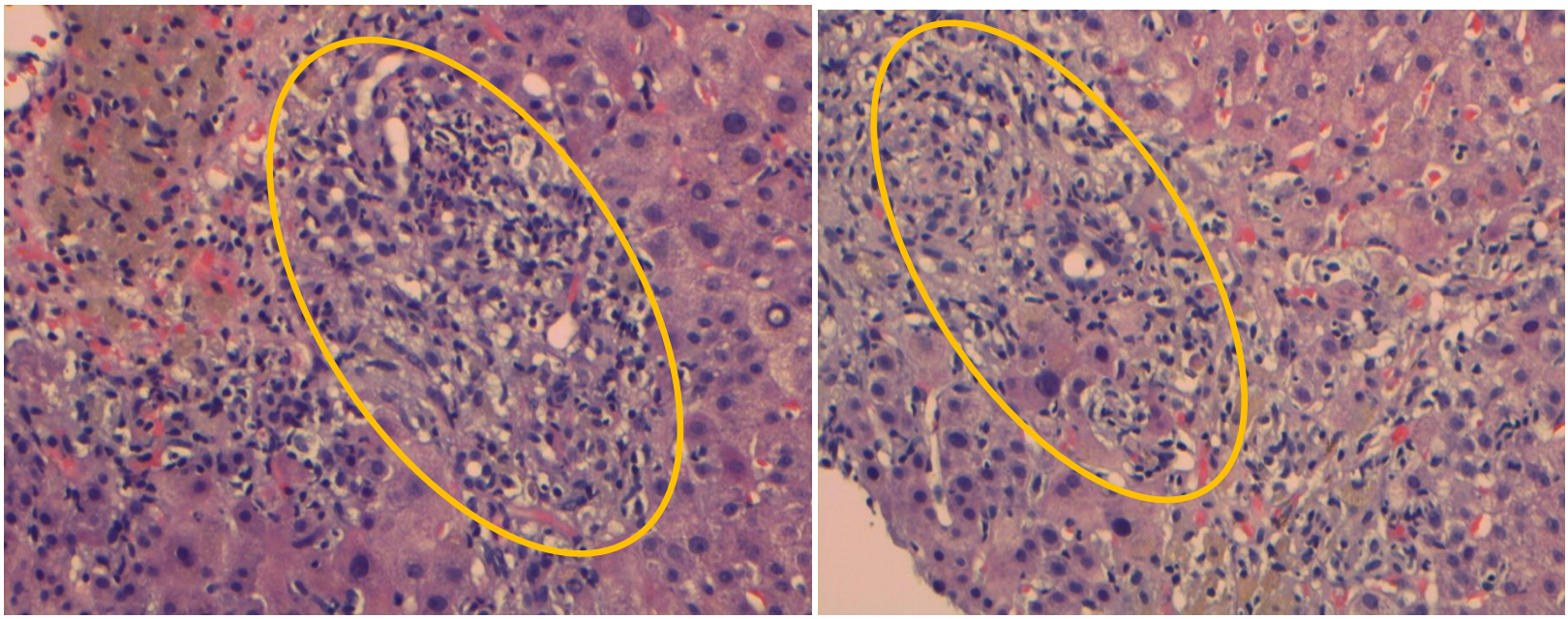

Figure 4: **High magnification of liver sections revealing epitheliod granulomas:** This section reveals a epitheloid granuloma which is dense cuff of demarcated tissue containing a population of lymphocytes and gaint langerhans cells. This represents a granulomatous inflammation in the liver tissue that can occur due to wide variety of causes including infection, autoimmune, toxic, allergic, neoplastic and drugs. In this clinical scenario, a combination of autoimmune, and drug induced causes could be possible implicated for their occurence.

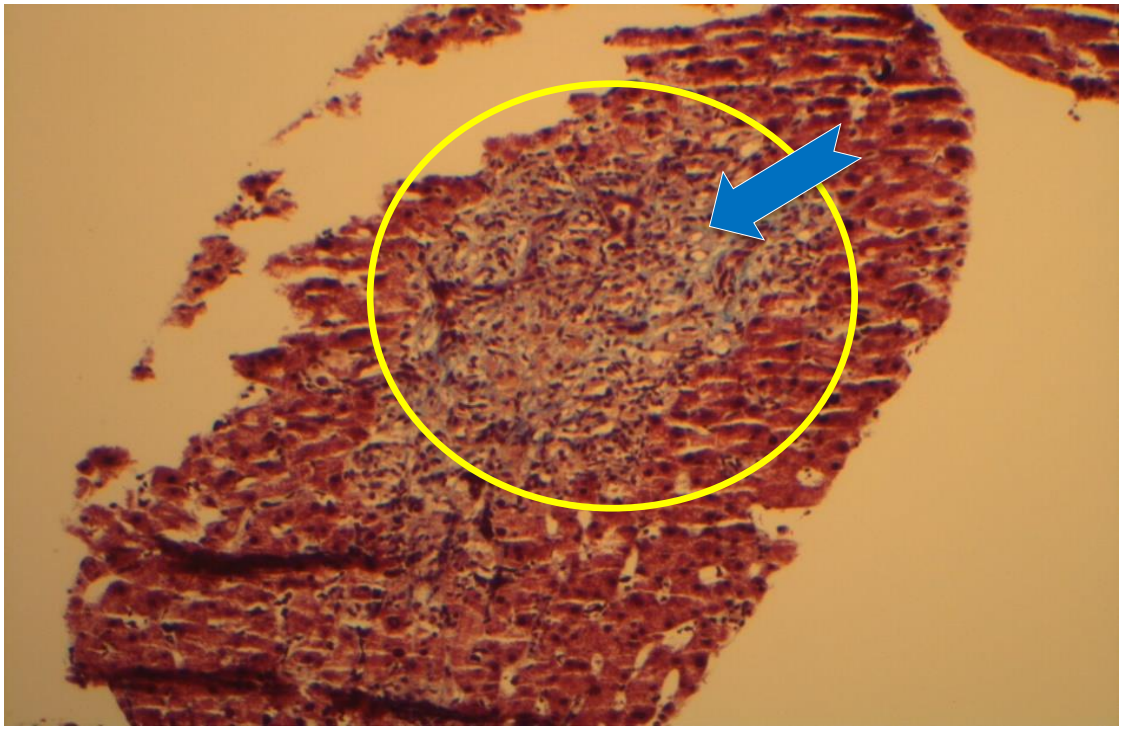

Figure 5: **Trichrome Staining of the liver tissue demonstrating fibrosis in the section**. In normal livers, we can expect that there is some collagen deposition in the portal veins but no collagen deposition around central veins. Collagenous tissue is stained blue with trichrome stain. In chronic liver, we can expect the fibrosis extending beyond the portal vein extending towards central vein in bridges and septae In the current section, we noticed that fibrotic area representing collagen deposition(stained blue) extending way beyond the portal area in septae, thus indicating the progression of autoimmune hepatitis towards chronic hepatitis and cirrhotic stage.

Figure 6**: CT Scan Abdomen/Pelvis with contrast:** This is the coronal view of the abdomen showing a non-occlusibe thrombus in the Inferior Vena Cava (IVC) [Yellow arrow]. Cirrhotic changes in the liver are described.

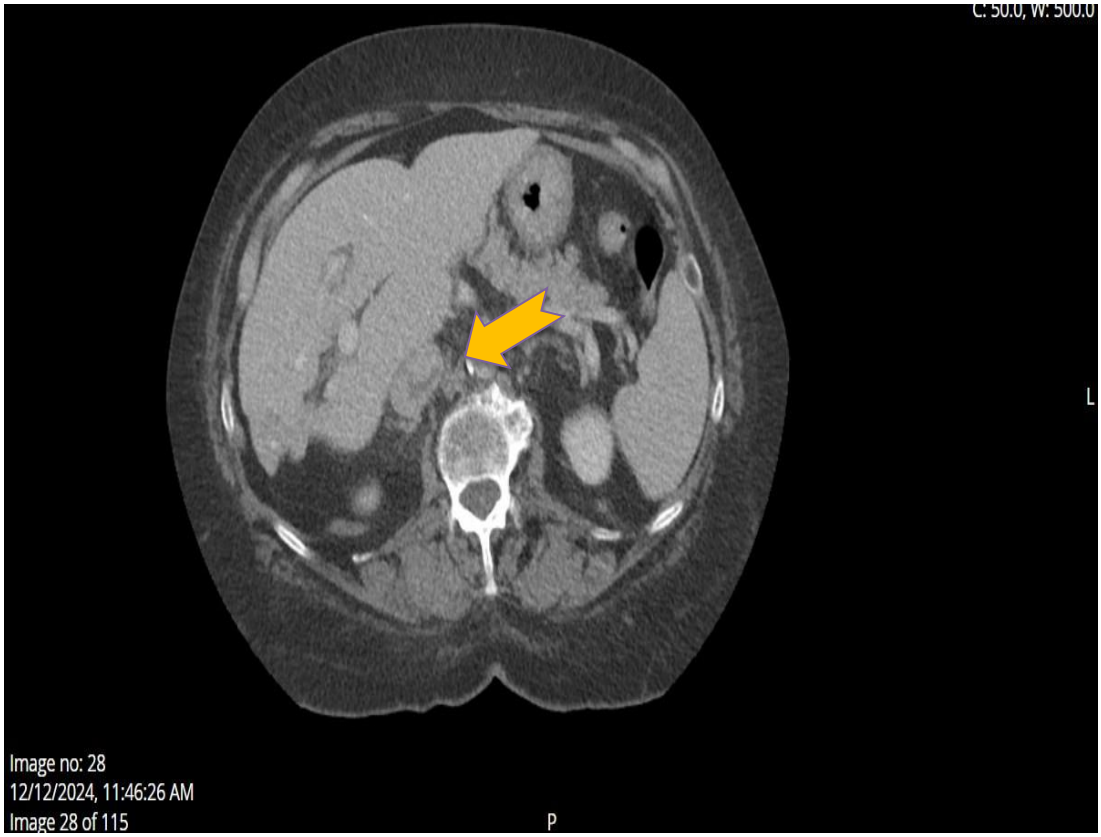

Figure 7**: CT Scan Abdomen/Pelvis with contrast:** This is a axial view of the abdomen showing a non-occlusibe thrombus in the Inferior Vena Cava (IVC) [Yellow arrow]. Cirrhotic changes in the liver are described.

Labs

	12-15-2020	06-07-2021	07-08-2022	07-21-2022	10-10-2022	10-17-2022	10-24-2022	11-22-2022
Bilirubin, Total			1.0 mg/dL	1.2 mg/dL				
Alkaline Phosphatase			80 U/L	87 U/L				
AST/SGOT			99 U/L	169 U/L	571	158	115	52
ALT/SGPT			146 U/L	238 U/L	652	271	185	70

	12-02-2022	01-18-2023	01-20-2023	02-20-2023	03-20-2023	03-27-2023	04-20-2023
Bilirubin, Total	2.1 mg/dL	2.4 mg/dL					
Alkaline Phosphatase	102 U/L	90 U/L					
AST/SGOT	42 U/L	35 U/L	36	49	65		41
ALT/SGPT	55 U/L	38 U/L	44	40	53		26

	05/19/23	06/20/23	07/17/23	12/06/23	1/30/24	3/6/24	3/28/24
Bilirubin, Total			1.2 mg/dL	1.1 mg/dL	0.9 mg/dL		
Alkaline Phosphatase			100 U/L	119 U/L	116 U/L		
AST/SGOT	37	30	39 U/L	35 U/L	102 U/L	59	70
ALT/SGPT	25	22	30 U/L	33 U/L	99 U/L	70	73

	06/13/24	06/18/24	07/29/24	08/07/24	08/12/24	08/29/24	09/12/24
Bilirubin, Total		2.1 mg/dL		1.8 mg/dL			
Alkaline Phosphatase		298 U/L		141 U/L			
AST/SGOT	218	411 U/L	74	60 U/L		41.5	49
ALT/SGPT	255	388 U/L	174	146 U/L		115	93

	10-01-2024	11-05-2024	12-05-2024
Bilirubin, Total			1.3 mg/dL
Alkaline Phosphatase			88 U/L
AST/SGOT	55	42	32 U/L
ALT/SGPT	81	45	36 U/L

Discussion

In our case, a 72-year old female patient who had been uneventfully treated with pravastatin for years presented with elevated liver enzymes. Pravastatin was discontinued, and autoimmune-like drug-induced liver injury (DILI) was diagnosed on liver biopsy. She initially had a resolution of her hepatitis after a four-month course of prednisone. She subsequently presented with another episode of hepatitis marked with elevation of LFTs greater than 10 times the upper limit of normal. Repeat liver biopsy showed similar histopathology, and because of a misrepresentation of the clinical background, it was concluded that she experienced a second drug-induced liver injury from ezetimibe. Because of the longitudinal nature of primary care, this error was quickly identified and subsequent evaluation by a hepatology-trained specialist led ultimately to the correct diagnosis: De Novo Autoimmune Hepatitis. She was successfully treated again with prednisone, although a longer duration was required before response, and subsequently transitioned to steroid-sparing immunosuppression with azathioprine. This case highlights both the similarities in histopathology of DILI and AIH, and contrasts the clinical and historical differences between the two. This case also highlights several risks associated with long-term, high dose corticosteroid treatment.

Given the clinical course of this case, drug-induced autoimmune hepatitis (rather than autoimmune-like drug induced liver injury) should be considered even after the initial liver biopsy. In a recent case report by Sonakshi, P. et al, a 65-year old patient with hypertension and hyperlipidemia, treated with amlodipine and atorvastatin, developed drug-induced autoimmune hepatitis with cholestasis syndrome, which marginally subsided following their discontinuation[10].Some of the drugs commonly implicated to induce AIH induce minocycline, nitrofurantoin, statins, ornidazole, melatonin and diclofenac [1]. Pravastatin used to treat this patient can potentially cause both DILI and AIH. DILI may have been less likely given to the chronicity of treatment with pravastatin medication. In contrast, statins may cause AIH by provoking autoimmunity in a patient with an underlying susceptibility. Ultimately, we hypothesize the latter is the most likely in this patient given the recurrence nearly a year after discontinuation of pravastatin. Historically, statins are well known to induce hepatocyte injury in a small proportion of patients through various mechanisms, including alteration of cytochrome P450 system, inciting mitochondrial oxidative stress, calcium-dependent permeability transition, genetic factors (transporter genes, cytochrome p450, ABCB1, ABCC1, and organic anion transporter peptides), thus triggering subsequent inflammation [11, 12].This is typically temporally related to initiation of treatment. However, this well-known adverse effect may have an underlying autoimmune mechanism. For example, a previous case report demonstrated the presence of anti-mitochondrial antibodies in a patient taking atorvastatin, thus highlighting the potential of statins to provoke an autoimmune response in the susceptible patients [11].

The pathogenesis of AIH comprises interplay of variety of different factors including genetic factors (DRB1 0201, 0301, 0401 & 0701), viruses (hepatitis viruses, measles viruses, Epstein-barr viruses, cytomegalovirus, and varicella-zoster virus), vitamin-D deficiency, intestinal barrier dysfunction, drugs (nitrofurantoin, minocycline, hydralazine, methyldopa, indomethacin, diclofenac, atorvastatin, Tienilic acid, interferon, TNF-α, and some Chinese herbal medicines), molecular mimicry, abnormal immune regulation (CD4+T cells, CD8 cytotoxicity and Treg cells) and auto-antibody production [13, 14]. Self-antigens presented by antigen presenting cells (APC) to a T-helper cell including human SepSecS-tRNASec complex (SEPSECS) [AIH-1], CYP2D6 and FTCD [AIH-2] are partially implicated in triggering the autoimmune cascade that ultimately leads to the onset of AIH. [15]. This nascent step could incite numerous downstream changes, including CD4+ T lymphocytes activation with overproduction of interferon-γ, functional impairment of T-regulatory cells, uprising of CD8+ T cells induced

factors like perforin and granzyme-B, increased γδ T cells, along with intra-portal B-cell accumulation with concomitant excess synthesis of IgG antibodies, all of which might synergistically favor the materialization of AIH[13]. The final hepatocyte destruction in AIH might be an end result of synchronous action of cytotoxic lymphocytes, cytokines, complement activation, and natural killer cells [13, 15].

A possible clinical scenario for inception of AIH in this patient could be due to a combination of factors including unmasking of self-antigens in the liver, drug-provoked procreation of autoantibodies, molecular mimicry, genetic susceptibility and precedent & dormant hepatotrophic viral infection. This patient also developed thrombocytopenia which could be the manifestation of autoimmunity directed at the patients platelets[16]. Other possible mechanisms of thrombocytopenia in this patient include drug induced (Statins), and portal hypertension from hepatic chirrosis (Sequestration of platelets)[16].

The histological hallmarks of AIH include peri-portal or peri-septal hepatitis with preponderantly copious accumulation of lympho-plasmacytic infiltrate [17]. Equally important for the diagnosis of AIH is the presence of interface hepatitis, which is characterized by hepatocyte injury at the peripheral areas with destruction of the limiting plate[15]. Not uncommonly, pan lobular hepatitis with bridging collapse can be present due to connective tissue damage extending from hepatic lobule to the portal area [15]. Liver biopsy in this patient revealed DILI (Portal & perivenular inflammation along with focal necroinflammatory bridging) on liver biopsy, but also consistent with the hallmark findings of autoimmune hepatitis (Liver architecture distortion by bridging necrosis and necroinflammatory activity extending from portal vein to central vein).

In severe cases, a lobular involvement with pyknotic necrosis, central-portal bridging necrosis, appearance of liver cell rosettes and nodular regeneration can be found [17]. Rarely, features such as lymphoid aggregates, steatosis, siderosis, cuprinosis, and bile ductule proliferation can stand out, the presence of which might not exclude the diagnosis of AIH [17].

AIH can be classified into types, contingent upon the presence of specific autoimmune antibodies. Elevation of anti-nuclear antibodies (ANA) or anti-smooth muscle antibodies (ASMA) will signify the presence of AIH type I whereas uprising of antibodies to Liver/Kidney microsomes (anti-LKM) or Liver cytosol (anti-LC-1) will imply the occurrence of AIH type II[6, 17, 18]. It is important to understand that, roughly 40% of the patient have Anti-ANA or anti-SMA antibodies while 3-4% of them have anti-LKM antibodies[19]. Upon checking the autoimmune antibodies in the blood, this patient had positive ANA (1:640) with normal ASMA & AMA levels, thus supportive of the diagnosis of AIH type-1. In patients having none of these antibodies in the serum, clinicians should look for alternative antibodies such as the hepatic asialoglycoprotein receptor (ASGP-R), a soluble liver antigen (SLA), a liver-specific cytosolic antigen (LC1), a liver-pancreas antigen (LP), glycosphingolipid sulfatide in hepatocyte plasma membranes, and peri-nuclear anti-neutrophil cytoplasmic antibodies (pANCA)[20-27]. The diagnostic criteria that are essential for diagnosis of AIH include serum abnormalities, hypergammaglobunaemia with IgG, typical histological diagnosis, and female with autoimmune disorders [17].

First line therapeutic agents usually employed for treatment of AIH include corticosteroids and azathioprine[15]. Corticosteroids act through binding through the membrane receptor and eventually migrate to the nucleus[15]. Once they reach the nucleus, they bind to the nuclear receptors and modulate the gene transcription by repressing the pro-inflammatory genes while energizing the anti-inflammatory genes[15]. On the other hand, azathioprine acts through depleting the levels of purine bases which are basic raw materials for DNA and RNA synthesis in actively dividing cells such as lymphocytes[15]. Initially, prednisolone is initiated with a dosage of 60 mg/day in acute severe cases whereas in all other cases 40mg/day would suffice[15]. The duration of prednisolone dosage should be very carefully titrated with liver transaminase enzyme levels in the

blood[15]. Less-optimal therapeutic responses characterized by static or uprising transaminase levels should be tackled by addition of azathioprine 0.5 mg/kg[15]. A rapid response to treatment is defined as a rapid decline in the transaminase levels in 8 weeks, a harbinger that might predict a good risk for lower rates of liver disease death or need for liver transplantation[28]. Poorer response to these first-line therapies might necessitate referral to the tertiary referral centers for the administration of second line (6-mercaptopurine, 6-thioguanine and mycophenolate mophetil) and third line (Calcineurin inhibitors [Cyclosporine A], Ritumunab, Anti-TNF inhibitors and TLR4 receptor antagonists) agents in case-by-case clinical scenarios[15]. This patient has been treated with prednisolone 40 mg and later gradually tapered to 10 mg in two separate occasions to manage her diagnosis of AIH-Like DILI (October 2022-Jan 2023) as subsequently diagnosed autoimmune hepatitis (June 2024-October 2024). These prolonged courses of corticosteroids did indeed cause two steroid-induced adverse effects, but these were recognized and well managed.

Some of the adverse effects of long term steroid therapy include diabetes, hypertension, infections, steroid induced myopathy, cushingoid features, stunted growth and delayed puberty, insomnia, psychiatric abnormalities, peptic ulcer disease, gastrointestinal bleeding, ophthalmic abnormalities, osteoporosis, cerebrovascular accidents, cataracts, avascular necrosis and heart failure [29, 30]. In our patient's case, she developed steroid induced gastritis, and was treated with pantoprazole with symptomatic remission. As a last therapeutic option, liver transplantation is advocated in a very small percentage of patients (4%) who are intolerant to immunosuppressive medications or in those whose AIH undergoes rapid progression to end-stage liver disease and liver failure[2, 31].

AIH is itself associated with increased propensity of developing portal vein thrombosis. In a cohort of 37 patients AIH patients waiting to undergo liver transplantation, portal vein thrombosis (PVT) is present in 30% of patients and these patients will unarguably benefit from anticoagulation [32]. Moreover, development of PVT in patients with AIH is an independent risk factor for the need of liver transplantation in patients with Autoimmune Hepatitis [33].

Along with the underlying disease (AIH), initiation of therapy with corticosteroids increases the risk of developing deep vein thrombosis (DVT) by at least 4-5 fold [34]. It is also shown that, the prognosis of steroid induced DVT is worse and risk of recurrence is 2-fold higher, thus emphasizing the importance of routine follow up in these patients [34]. The mechanism of steroid induced DVT can be due to increased coagulation factors (VII [13%], VIII [27%], IX [6%] and fibrinogen [13%]), along with heightened synthesis of PAI-1 and VWF (Von Will brand factor) [35, 36]. Histopathological examination has uncovered a cirrhotic morphology of liver in this patient. That being said, cirrhotic patients are increasingly liable to develop deep vein thrombosis. The spectrum of changes in the blood of cirrhotic patients including decreased levels of anticoagulant factors [anti-thrombin III, Protein C & protein S] due to lessened synthesis, increased pro-coagulants factors [Factor VIII and VWF] and genetic factors like factor V Leiden might have heightened the risk of developing IVC thrombosis in this patient[37]. Increased VWF in cirrhotic patients is bound to be a triggering factor for enhanced platelet aggregation and perpetuation of factor VIII, thus paving the way for preponderance of pro-coagulant arm in these patients [38, 39]. Chronic thrombocytopenia present in this patient can be another independent risk factor for developing IVC thrombosis in this patient [40, 41].

Conclusions

Our clinical case describes a clinical scenario where an elderly female presented initially with elevated LFTs and with elevated auto-antibodies, thus leading to the diagnosis of DILI with autoimmune component. Steroid therapy resulted in disease remission, but their discontinuation lead to disease relapse with severe elevation of LFTs and signs of autoimmune hepatitis. It is important to understand that, discontinuation of steroids does not case relapse of DILI, but resurgence of autoimmune hepatitis is almost universal after

their discontinuation. This clinical case highlights the presentation of autoimmune hepatitis disguising as DILI. IVC thrombosis noted in this patient can be the end result of autoimmune phenomenon and long-term steroid therapy. Prompt diagnosis and treatment with steroids is essential for preventing immune mediated hepatocyte destruction. Inducing disease remission will avert major complications and disease progression towards chronic liver failure, cirrhosis and hepatocellular carcinoma.

References:

1. Sucher, E., R. Sucher, T. Gradistanac, G. Brandacher, S. Schneeberger, and T. Berg, Autoimmune Hepatitis-Immunologically Triggered Liver Pathogenesis-Diagnostic and Therapeutic Strategies. J Immunol Res, 2019. 2019: p. 9437043.
2. Shrestha, M., S.C. Subedi, S. Shah, J. Acharya, M. Regmi, and N. Mehta, Autoimmune Hepatitis Leading to Liver Cirrhosis: A Case Report. JNMA J Nepal Med Assoc, 2022. 60(256): p. 1059-1062.
3. Floreani, A., P. Restrepo-Jiménez, M.F. Secchi, S. De Martin, P.S.C. Leung, E. Krawitt, et al., Etiopathogenesis of autoimmune hepatitis. J Autoimmun, 2018. 95: p. 133-143.
4. Delgado, J.S., A. Vodonos, S. Malnick, O. Kriger, R. Wilkof-Segev, B. Delgado, et al., Autoimmune hepatitis in southern Israel: a 15-year multicenter study. J Dig Dis, 2013. 14(11): p. 611-8.
5. Hurlburt, K.J., B.J. McMahon, H. Deubner, B. Hsu-Trawinski, J.L. Williams, and K.V. Kowdley, Prevalence of autoimmune liver disease in Alaska Natives. Am J Gastroenterol, 2002. 97(9): p. 2402-7.
6. Jo, H.I., M. Kim, J.J. Yoo, S.G. Kim, Y.S. Kim, and S. Chin, Acute Hepatitis A-Induced Autoimmune Hepatitis: A Case Report and Literature Review. Medicina (Kaunas), 2022. 58(7).
7. Wang, Q.X., L. Yan, and X. Ma, Autoimmune Hepatitis in the Asia-Pacific Area. J Clin Transl Hepatol, 2018. 6(1): p. 48-56.
8. EASL Clinical Practice Guidelines: Autoimmune hepatitis. J Hepatol, 2015. 63(4): p. 971-1004.
9. Kanzler, S., G. Gerken, H. Löhr, P.R. Galle, K.H. Meyer zum Büschenfelde, and A.W. Lohse, Duration of immunosuppressive therapy in autoimmune hepatitis. J Hepatol, 2001. 34(2): p. 354-5.
10. Joshi, S., A. Davies, and J. Ghumman, S3142 Rare Case of Drug-Induced Autoimmune Hepatitis. Official journal of the American College of Gastroenterology | ACG, 2022. 117(10S): p. e2018.
11. Kuniyoshi, N., H. Miyakawa, K. Matsumoto, H. Tsunashima, K. Sekine, T. Tsujikawa, et al., Detection of Anti-mitochondrial Antibodies Accompanied by Drug-induced Hepatic Injury due to Atorvastatin. Intern Med, 2019. 58(18): p. 2663-2667.
12. Averbukh, L.D., A. Turshudzhyan, D.C. Wu, and G.Y. Wu, Statin-induced Liver Injury Patterns: A Clinical Review. Journal of Clinical and Translational Hepatology, 2022. 10(3): p. 543-552.
13. Sirbe, C., G. Simu, I. Szabo, A. Grama, and T.L. Pop, Pathogenesis of Autoimmune Hepatitis-Cellular and Molecular Mechanisms. Int J Mol Sci, 2021. 22(24).
14. Fan, J.H., G.F. Liu, X.D. Lv, R.Z. Zeng, L.L. Zhan, and X.P. Lv, Pathogenesis of autoimmune hepatitis. World J Hepatol, 2021. 13(8): p. 879-886.
15. Terziroli Beretta-Piccoli, B., G. Mieli-Vergani, and D. Vergani, Autoimmmune hepatitis. Cellular & Molecular Immunology, 2022. 19(2): p. 158-176.
16. Gauer, R.L. and M.M. Braun, Thrombocytopenia. Am Fam Physician, 2012. 85(6): p. 612-22.
17. Alvarez, F., P.A. Berg, F.B. Bianchi, L. Bianchi, A.K. Burroughs, E.L. Cancado, et al., International Autoimmune Hepatitis Group Report: review of criteria for diagnosis of autoimmune hepatitis. Journal of Hepatology, 1999. 31(5): p. 929-938.
18. Krawitt, E.L., Autoimmune hepatitis. N Engl J Med, 2006. 354(1): p. 54-66.
19. Johnson, P.J. and I.G. McFarlane, Meeting report: International Autoimmune Hepatitis Group. Hepatology, 1993. 18(4): p. 998-1005.
20. Abuaf, N., C. Johanet, P. Chretien, E. Martini, E. Soulier, S. Laperche, et al., Characterization of the liver cytosol antigen type 1 reacting with autoantibodies in chronic active hepatitis. Hepatology, 1992. 16(4): p. 892-8.
21. Treichel, U., B.M. McFarlane, T. Seki, E.L. Krawitt, N. Alessi, F. Stickel, et al., Demographics of anti-asialoglycoprotein receptor autoantibodies in autoimmune hepatitis. Gastroenterology, 1994. 107(3): p. 799-804.
22. Stechemesser, E., R. Klein, and P.A. Berg, Characterization and clinical relevance of liver-pancreas antibodies in autoimmune hepatitis. Hepatology, 1993. 18(1): p. 1-9.
23. Toda, G., Y. Ikeda, M. Kashiwagi, M. Iwamori, and H. Oka, Hepatocyte plasma membrane glycosphingolipid reactive with sera from patients with autoimmune chronic active hepatitis: its identification as sulfatide. Hepatology, 1990. 12(4 Pt 1): p. 664-70.
24. Lenzi, M., P. Manotti, L. Muratori, M. Cataleta, G. Ballardini, F. Cassani, et al., Liver cytosolic 1 antigen-antibody system in type 2 autoimmune hepatitis and hepatitis C virus infection. Gut, 1995. 36(5): p. 749-54.
25. Han, S., M. Tredger, G.V. Gregorio, G. Mieli-Vergani, and D. Vergani, Anti-liver cytosolic antigen type 1 (LC1) antibodies in childhood autoimmune liver disease. Hepatology, 1995. 21(1): p. 58-62.
26. McFarlane, I.G. and R. Williams, Liver membrane antibodies. J Hepatol, 1985. 1(3): p. 313-9.

27. Czaja, A.J., H.A. Carpenter, and M.P. Manns, Antibodies to soluble liver antigen, P450IID6, and mitochondrial complexes in chronic hepatitis. Gastroenterology, 1993. 105(5): p. 1522-8.
28. Pape, S., T.J.G. Gevers, J.M. Vrolijk, B. van Hoek, G. Bouma, C.M.J. van Nieuwkerk, et al., Rapid Response to Treatment of Autoimmune Hepatitis Associated With Remission at 6 and 12 Months. Clinical Gastroenterology and Hepatology, 2020. 18(7): p. 1609-1617.e4.
29. Koshi, E.J., K. Young, J.C. Mostales, K.B. Vo, and L.P. Burgess, Complications of Corticosteroid Therapy: A Comprehensive Literature Review. J Pharm Technol, 2022. 38(6): p. 360-367.
30. Yasir M, G.A., Sonthalia S. , Corticosteroid Adverse Effects, in StatPearls [Internet]. 2023, StatPearls Publishing: Treasure Island (FL).
31. Manns, M.P., A.W. Lohse, and D. Vergani, Autoimmune hepatitis--Update 2015. J Hepatol, 2015. 62(1 Suppl): p. S100-11.
32. Ruiz, P., L. Sastre, G. Crespo, A. Blasi, J. Colmenero, J.C. García-Valdecasas, et al., Increased risk of portal vein thrombosis in patients with autoimmune hepatitis on the liver transplantation waiting list. Clin Transplant, 2017. 31(7).
33. Kilaru, S.M., G. Quarta, and V. Popov, Portal Vein Thrombosis and Coagulopathy Are Independent Risk Factors for the Increase in Liver Transplantation for Autoimmune Hepatitis in the United States: 921. Official journal of the American College of Gastroenterology | ACG, 2017. 112: p. S515-S516,S518-S519.
34. Orsi, F.A., W.M. Lijfering, G.J. Geersing, F.R. Rosendaal, O.M. Dekkers, S. le Cessie, et al., Glucocorticoid use and risk of first and recurrent venous thromboembolism: self-controlled case-series and cohort study. Br J Haematol, 2021. 193(6): p. 1194-1202.
35. Brotman, D.J., J.P. Girod, A. Posch, J.T. Jani, J.V. Patel, M. Gupta, et al., Effects of short-term glucocorticoids on hemostatic factors in healthy volunteers. Thromb Res, 2006. 118(2): p. 247-52.

36. Majoor, C.J., M.M.S. Sneeboer, A. de Kievit, J.C.M. Meijers, T. van der Poll, R. Lutter, et al., The influence of corticosteroids on hemostasis in healthy subjects. Journal of Thrombosis and Haemostasis, 2016. 14(4): p. 716-723.
37. Aggarwal, A., K. Puri, and S. Liangpunsakul, Deep vein thrombosis and pulmonary embolism in cirrhotic patients: systematic review. World J Gastroenterol, 2014. 20(19): p. 5737-45.
38. Lisman, T., T.N. Bongers, J. Adelmeijer, H.L. Janssen, M.P. de Maat, P.G. de Groot, et al., Elevated levels of von Willebrand Factor in cirrhosis support platelet adhesion despite reduced functional capacity. Hepatology, 2006. 44(1): p. 53-61.
39. Hollestelle, M.J., H.G. Geertzen, I.H. Straatsburg, T.M. van Gulik, and J.A. van Mourik, Factor VIII expression in liver disease. Thromb Haemost, 2004. 91(2): p. 267-75.
40. Wang, L., E. Wall, J.M. Patterson, C.M. Wu, and H.L. Sun, Management and Outcomes of Venous Thromboembolism in Adults with Immune Thrombocytopenia. Blood, 2022. 140(Supplement 1): p. 55-56.
41. Goncalves, I., C. Lewis, B. Grainger, R. Dring, N. Lee, S.-R. Pasricha, et al., Thrombosis in patients with immune thrombocytopenia: incidence, risk, and clinical outcomes. Research and Practice in Thrombosis and Haemostasis, 2024. 8(1): p. 102342.