

Case Report

## VV- ECMO as a Rescue Manuever in a Severe Case of Asthma After Use of Hookah

Ellen Pierre de Oliveira<sup>1</sup>, Samuel Lucas dos Santos<sup>1</sup>, Glauco Cabral Marinho Plens<sup>1</sup>, Izabela Silva Guizellini<sup>1</sup>, Yannky Alberto Lopez<sup>1</sup>, Marcelo Britto Passos Amato<sup>1</sup>, Carmen Silvia Valente Barbas<sup>1</sup>

<sup>1</sup>Instituto do Coração –INCOR- HCFMUSP – São Paulo, SP, Brazil

**\*Corresponding Author:** Carmen Silvia Valente Barbas and Ellen Pierre de Oliveira, Instituto do Coração – INCOR- HCFMUSP – São Paulo, SP, Brazil

### Introduction

A 16-year-old woman with a history of poorly controlled asthma and a particular use of hookah was admitted to the emergency room of Hospital Irmandade da Santa Casa de Misericórdia, Sorocaba, São Paulo, Brazil on March 24th, 2023.

Seven days before admission, she had used hookah at a party with friends and then she started with a discrete wheezing that got worse in the following days. She started oral prednisone and salbutamol as needed. Due to the persistence of symptoms and limitation to daily activities, she went to the emergency room.

After admission, methylprednisolone 40 mg/day, ceftriaxone and azithromycin were started. Despite initial treatment she didn't improve and started the use of high flow oxygen. She was transferred to the intensive care unit on March 25th and was intubated and mechanically ventilated due to refractory bronchospasm and worsening of hypoxia.

After optimization of bronchodilators and inhaled corticosteroids, protective ventilation was initiated with neuromuscular blockade. Due to persistent hypoxemia, prone position was initiated without improvement of hypoxemia ( $PaO_2/FiO_2 = 75.6$ ) and hypercapnia ( $PaCO_2 = 117.5$  mmHg). Because of the clinical refractoriness, on April 6th, 2023, the case was discussed with the ECMO team at INCOR Institute and veno-venous cannulation with extracorporeal support was indicated as a ransom measure for both hypoxemia and hypercapnia.

A specialized ECMO team composed of two pulmonologists, three thoracic surgeons and two perfusionists traveled from São Paulo (capital of the state of São Paulo) to Sorocaba (state of São Paulo) to cannulate the patient at the hospital of origin (figure 1) and bring her by ambulance to the INCOR reference center of ECMO to continue her treatment.

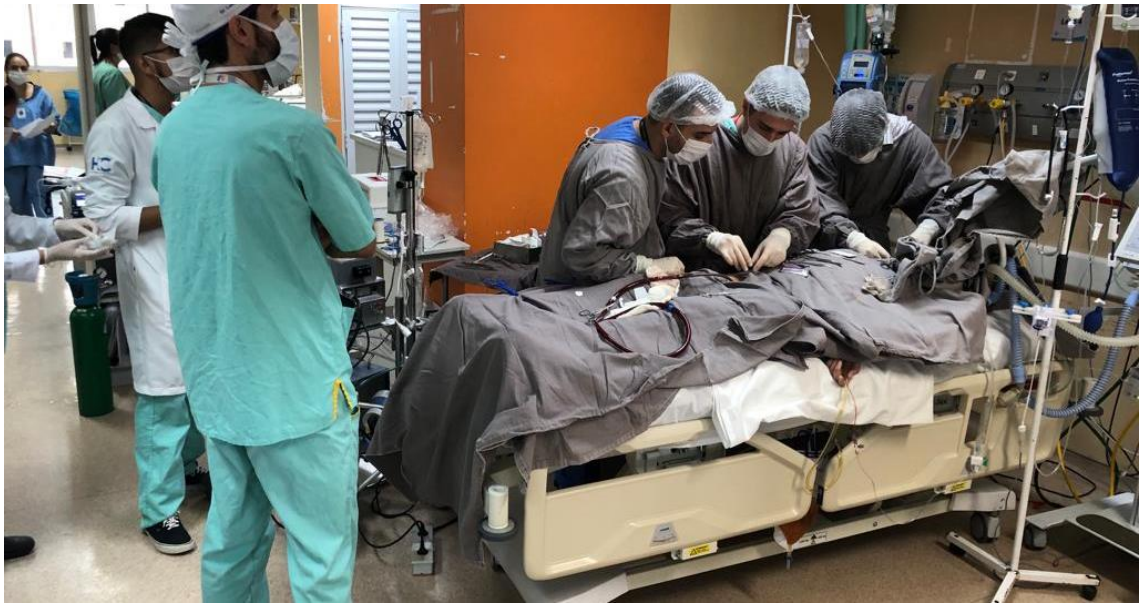

Figure 1. VV-ECMO cannulation at the hospital of origin by the ECMO specialized team of INCOR-Respiratory ICU.

At hospital admission in INCOR - Respiratory Unit ICU, ECMO parameters were flow of 4,3 L/min, FIO<sub>2</sub> of 100% and sweep gas 3L/min. The patient was ventilated in Servo Ventilator (Maquet®) in pressure-controlled ventilation of 10 cmH<sub>2</sub>O. Arterial blood gas analysis showed PaCO<sub>2</sub> of 48 mmHg and PaO<sub>2</sub> of 73 mmHg. Chest -X ray at that moment showed atelectasis at both lung bases.

(Figure 2)

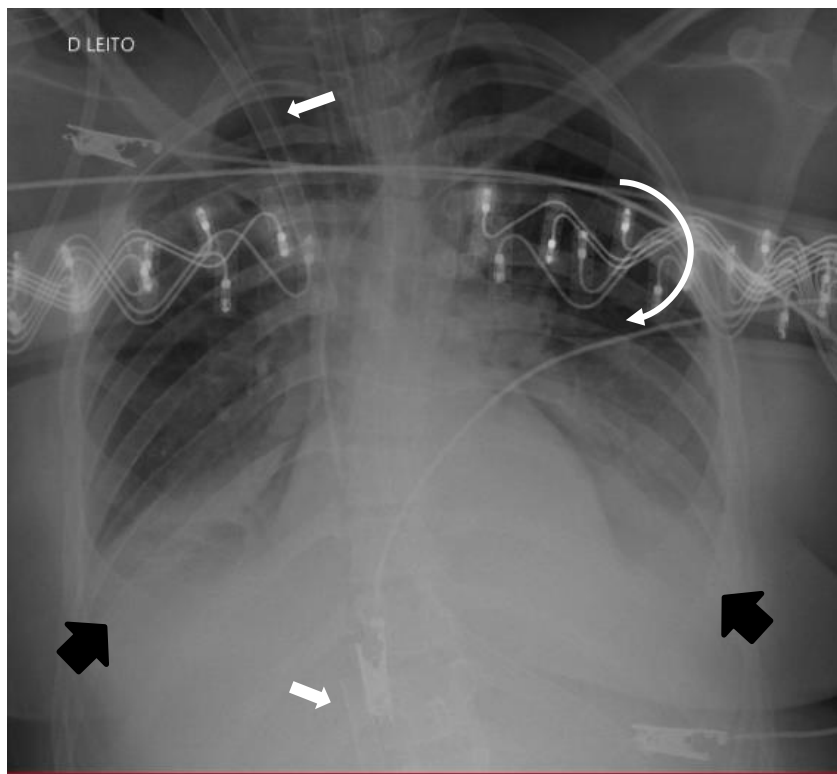


Fig 2: Chest X ray showing atelectasis of both pulmonary bases. White arrow – ECMO cannulas; black arrow – pulmonary atelectasis; Curve arrow – electrical impedance tomography

The monitoring by thoracic electrical impedance tomography showed a loss of posterior aeration which may correspond to the lungs bases atelectasis seen in the chest -X-ray (Figure 3)

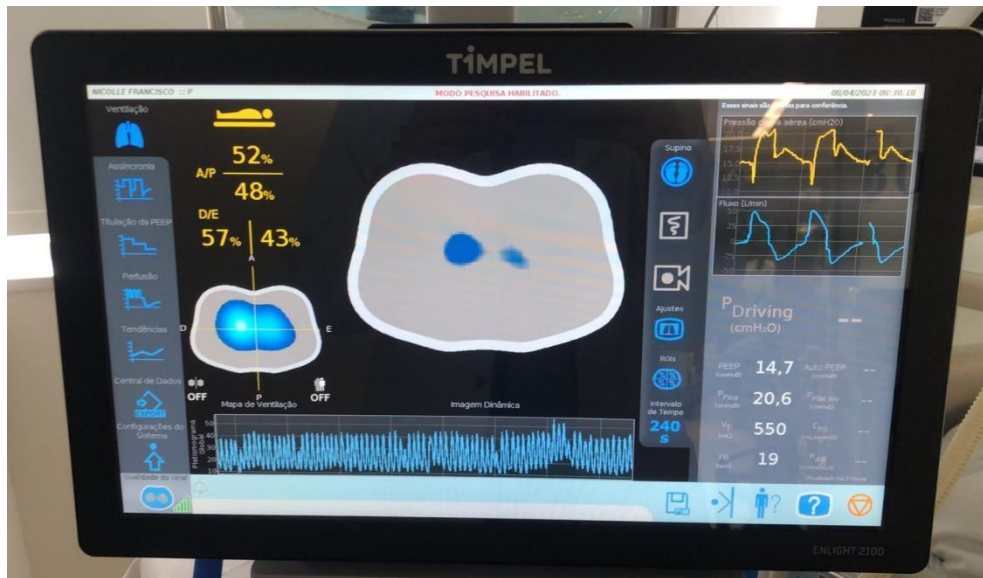


Figure 3: Thoracic electrical impedance tomography showing loss of pulmonary aeration in the posterior region of the lung.

The admission exams at the INCOR showed a leukocytosis of 19.000 mm<sup>3</sup>/dL, C-reactive protein of 154 mg/dL and pro-calcitonin of 0.24 ng/mL, the antibiotics meropenem and vancomycin were in and a bronchoscopy was requested for evaluation of the bronchial tree.

The bronchoscopy was performed with visualization and removal of secretion plugs from the bronchi of the lower lobes with improvement in lung aeration. The figure 4 showed the improvement of radiological image of the chest X-ray.

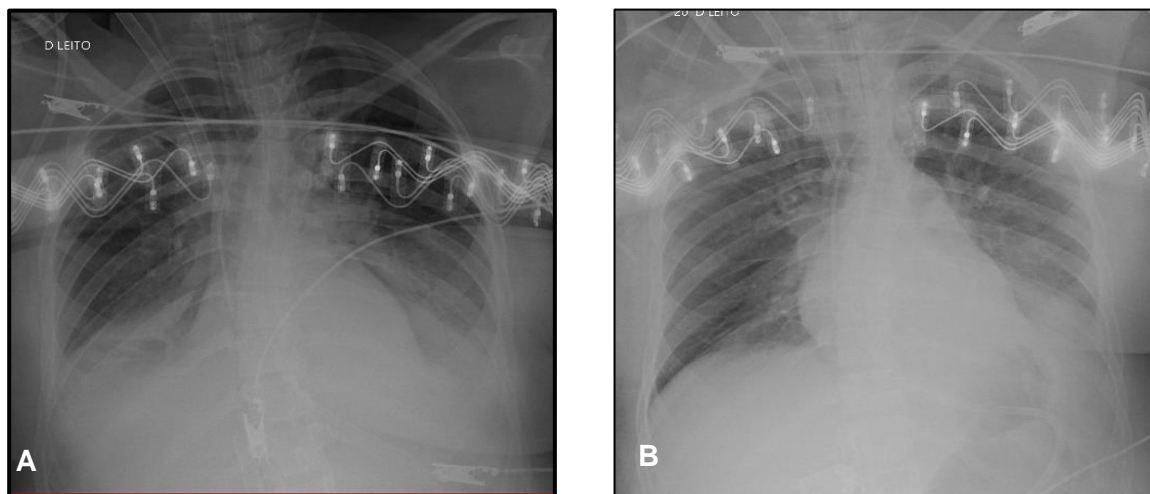


Figure 4 A – Chest X-ray before bronchoscopy  
B – Chest X-ray after bronchoscopy

Due to the great clinical improvement after hygienic bronchoscopy the ECMO weaning test was performed, and the patient was decannulated with success. After ECMO decannulation, the patient passed a Spontaneous breathing trial and was successfully extubated. Inhaled medications for asthma and respiratory physiotherapy were optimized, the patient was discharged for outpatient follow-up.

## **Discussion:**

Hookah originates from India and recently spread around the world. Recent studies showed that it can be more harmful than the cigarette, becoming a public health problem. Hookah increases airway inflammation, causing bronchospasm and respiratory infection(1). The hookah users can evolve with wheezing, cough, sputum, and shortness of breath. Its use can significantly decrease pulmonary function parameters, including FEV1, FEV1/FVC ratio, as well as the levels of FeNO, and can worsen airway reactivity.(2)

In asthmatic patients the possible treatment is the use of inhaled bronchodilators and corticosteroids, systemic corticosteroids, high-flow oxygen, and non-invasive ventilation. If the patient needs intubation and mechanical ventilation, sedative with bronchodilator action such as ketamine can be used and in more severe cases the use of neuromuscular blockers and veno-venous ECMO can be indicated (3).

V-V ECMO for pulmonary rescue has an important benefit in very severe asthmatic patients trying to avoid barotrauma and to maintain the protective ventilation (4) and when instituted earlier better will be the results. ECMO is used to allow lung rest in severe cases and asthma attack reversion. In this case, the monitoring with chest-X-ray and electrical impedance tomography suggested loss of lung bases aeration. Mucus plugs are known to be common in patients with severe Asthma and the higher the mucus plugs score, higher the airway obstruction severity Mucus plugs were also associated with distal deficits in regional ventilation as delineated by hyperpolarized gas magnetic resonance imaging. Evaluation of a lung image like thoracic tomography in inspiration/expiration in Asthma patients can add the diagnosis of bronchial thickness, air-trapping, and hyperinflation and possible bronchiectasis (5)

In the case presented, the bronchoscopy was only concomitant with VV-ECMO, because of the severity of the case, allowing the possibility of mucus plugs removal and a better ventilation and re-aeration of lung bases. After the lifesaving procedure, the pulmonary function of the patient improved, and she could be liberated from the mechanical ventilator with success. After hospital discharge, she was oriented not to use hookah, and an asthma care educational program was initiated in INCOR - HCFMUSP outpatient ambulatory. Ten months after this severe episode she is asymptomatic in use of inhaled corticosteroids and long action beta-2 agonists.

## References:

1. Oliveira EP, Tavares MS, Carvalho CRR, Barbas CSV. The Hookah, an Emerging Form of Smoking, Systemic Effects and Harmful Effects of Its Use. *Medical Research Archives*. v. 10, n. 12, dec. 2022. ISSN 2375-1924
2. Qasim H, Alarabi AB, Alzoubi KH, Karim ZA, Alshbool FZ, Khasawneh FT. The effects of hookah/waterpipe smoking on general health and the cardiovascular system. *Environ Health Prev Med*. 2019;24(1):58.
3. Venkatesan P. 2023 GINA report for asthma. *Lancet Respir Med*. 2023 Jul;11(7):589. doi: 10.1016/S2213-2600(23)00230-8. PMID: 37302397.
4. Gayen S, Dachert S, Kim E, Gordon M, Shenoy K, Desai P. Single-institution experience of extracorporeal membrane oxygenation for near-fatal asthma. *Respir Med Case Rep*. 2023 Dec 12;46:101963. doi: 10.1016/j.rmcr.2023.101963.
5. Do Biologic Therapies Decrease Mucus Plugging in Asthma? Krings JG, Gierada DS. *NEJM Evid*. 2023 Oct;2(10): EVIDe2300179. doi: 10.1056/EVIDe2300179. Epub 2023 Sep 26. PMID: 38320185

Citation: Carmen Silvia Valente Barbas and Ellen Pierre de Oliveira, *Arch Med Clin Case Stud*, “VV- ECMO as a Rescue Manuever in a Severe Case of Asthma After Use of Hookah”. 2024; 1(1): 103

Received Date: February 19, 2024; Published Date: February 26, 2024

Copyright: © 2024 Carmen Silvia Valente Barbas and Ellen Pierre de Oliveira. This is an open-access article distributed under the terms of the Creative Commons Attribution License.